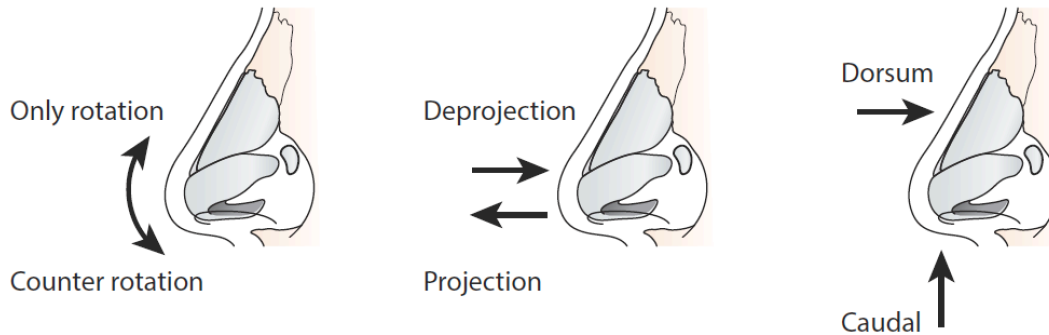


Rhinoplasty Examination Questions

D. Julian De Silva MBBS, MD, FACS



I. List the common indications for patients undergoing rhinoplasty:

- A. Aesthetic: Large nose, nasal hump, wide nose, droopy nasal tip (Figure 1)
- B. Functional: Difficult breathing and deviated septum
- C. Congenital: Cleft lip & palate, congenital nasal abnormalities
- D. Traumatic nasal fracture
- E. Inflammatory conditions: connective tissue disorders, immune disorders
- F. Iatrogenic: recreational drug use, cocaine

II. List the important anatomical structures within the nose

- A. Cartilages
 - 1. Lower lateral cartilages (Figure 2)
 - 2. Upper lateral cartilages (Figure 2)
 - 3. Septal cartilage (Figure 2)
- B. Nasal Bones (Figure 2)
- C. Nasal SMAS (Superficial muscular aponeurotic system: Soft tissue envelope that is beneath the skin and above the bone and cartilage, continuous with SMAS layer of forehead)
- D. Skin envelope

III. Describe the directional anatomical terms for rhinoplasty:

- A. Rotation vs. Counter-rotation (Figure 3)
- B. Projection vs. Deprojection (Figure 3)
- C. Dorsal vs. Caudal (Figure 3)